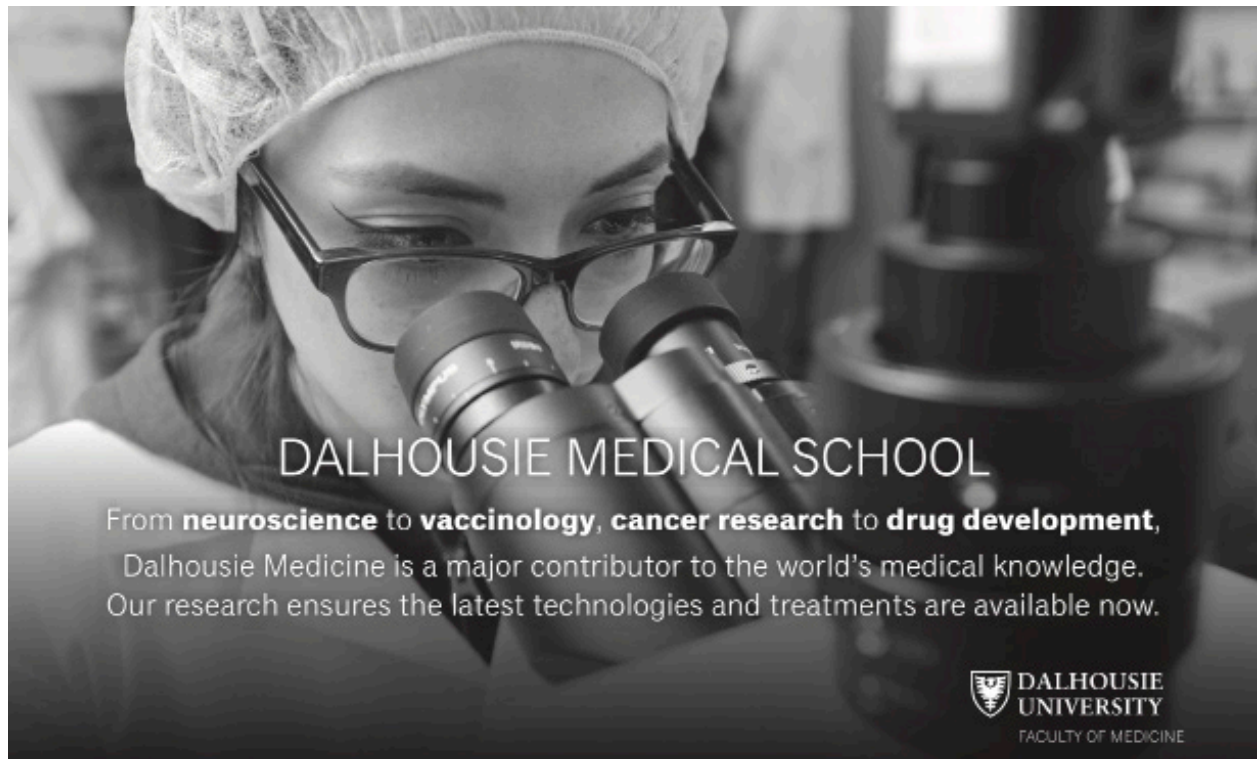



DIAGNOSE THIS

A recurrent lump on the hand

Miso Gostimir BSc¹, Rosalind Ashton MD², Joel Werier MD FRCSC³

¹Class of 2017, Faculty of Medicine, University of Ottawa

²Plastic and Reconstructive Surgery, Faculty of Medicine, University of Ottawa

³Division of Orthopedic Surgery, Faculty of Medicine, University of Ottawa

A 32-year-old male presented with a 6-month history of a slowly expanding painful mass on the radial aspect of his right middle finger. The mass measured 1.5 x 1.0 cm with no irregularities in the overlying skin, neurovascular status, or joint range of motion. Radiographs were interpreted as showing an exostosis or osteochondroma. The lesion was resected but recurred one year later. A clinical photograph and plain x-ray are shown (Figure 1).

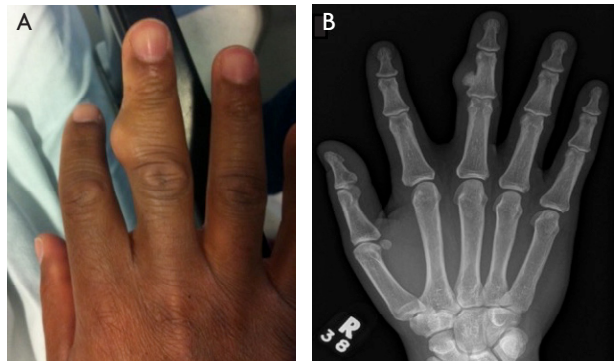


Figure 1. A photograph (A) and radiograph (B) of the right middle finger associated with a recurrent lump.

Choose the best answer after reviewing the figures:

- A. The recurrent nature of this seemingly benign-looking lesion should alert the clinician to the possibility of metastatic disease
- B. MRI is required to properly diagnose this lesion
- C. A key finding of this lesion is its lack of medullary involvement
- D. The lesion should be radiated prior to surgical excision
- E. The painful presentation should alert the clinician to the possibility of malignancy

After repeat resection, the diagnosis was revised to bizarre parosteal osteochondromatous proliferation (BPOP) due to its recurrent nature, progressive ossification of the lesion, and cortical irregularities of the middle phalanx adjacent to the lesion. The lesion recurred for a third time over the course of five years, reaching a size of 2.0 x 1.2 cm and involving the overlying skin. Resection necessitated removal of overlying skin and soft tissue coverage with local finger flap.

Occasionally referred to as Nora's lesion after pathologist Dr. F. Nora who first described it in 1983,¹ BPOP is a rare benign fibro-osseous mass which arises from the periosteum and often presents in the hands and feet during the third and fourth decades of life. It affects the hands almost four times as often as the feet,² though it has been described in the mandible as well as long bones.³ BPOP is often misdiagnosed as osteochondroma due to its similar gross appearance. However, BPOP differs from osteochondroma in that it does not have medullary continuity with the underlying bone and has a distinct blue colouration histologically upon eosin-hematoxylin staining.⁴ An anatomical pathologist should examine all resected specimen. Nora's lesions can also be distinguished from an osteochondroma by its lack of cartilage cap; the periosteum demonstrates a bizarre mix of bone and fibrous tissue. In contrast, more organized normal bone pathology is found beneath the cartilage cap of an osteochondroma. On physical examination, the lesion rarely causes any neurovascular disturbances and may or may not be associated with pain. Plain radiographs are sufficient for imaging.

Treatment is local surgical excision, even for recurrent lesions. There is no role for chemotherapy

or radiation. Surgery should address the lesion, surrounding periosteum, and decortication of underlying bone, though there is no consensus on how wide margins should be.⁵ Ligament reconstruction should be performed if these are disturbed at the time of excision. Unfortunately, it has a markedly high frequency of recurrence, with up to 55% of patients reported to have at least one recurrence requiring repeat surgical excision.⁶ There have been no documented reports of metastasis or deaths from this lesion.

References

1. Nora FE, Dahlin DC, Beabout JW. Bizarre parosteal osteochondromatous proliferations of the hands and feet. *Am J Surg Pathol* 1983;7(3):245-50.
2. Chamberlain AM, Anderson KL, Hoch B, Trumble TE, Weisstein JS. Benign parosteal osteochondromatous proliferation of the hand originally diagnosed as osteochondroma: a report of two cases and review. *Hand (New York, NY)* 2010;5(1):106-10.
3. Abramovici L, Steiner GC. Bizarre parosteal osteochondromatous proliferation (Nora's lesion): a retrospective study of 12 cases, 2 arising in long bones. *Hum Pathol* 2002;33(12):1205-10.
4. Brien EW, Mirra JM, Luck JV, Jr. Benign and malignant cartilage tumors of bone and joint: their anatomic and theoretical basis with an emphasis on radiology, pathology and clinical biology. II. Juxtacortical cartilage tumors. *Skeletal radiology* 1999;28(1):1-20.
5. Ting BL, Jupiter J. Recurrent bizarre parosteal osteochondromatous proliferation of the ulna with erosion of the adjacent radius: case report. *J Hand Am Surgery* 2013;38(1):2381-6
6. Meneses MF, Unni KK, Swee RG. Bizarre parosteal osteochondromatous proliferation of bone (Nora's lesion). *Am J Surg Pathol* 1993;17(7): 691-7.