

The Case of the Man with Bad Breath

Chris Diamond¹, BSc., MD '01, and Mark E. P. Prince², MD, FRCSC

¹Dalhousie University Faculty of Medicine, Halifax, N.S.

²Division of Otolaryngology, QEII Health Sciences Centre, Halifax, N.S.

A 67 year old man presents to the ENT clinic one afternoon complaining of increasing difficulty swallowing. He notes he frequently regurgitates undigested food particles and has very bad breath. These problems have been worsening over the past 6 months and have become quite bothersome. The remainder of his history is unremarkable. You complete a thorough physical examination of the head and neck which reveals little. A barium swallow is ordered and the results are shown in Figure 1.

- Q1: Can you identify the abnormality seen in the barium esophagram?
- Q2: What other investigations should be ordered?
- Q3: What is the likely diagnosis?
- Q4: **What are the treatment options?**

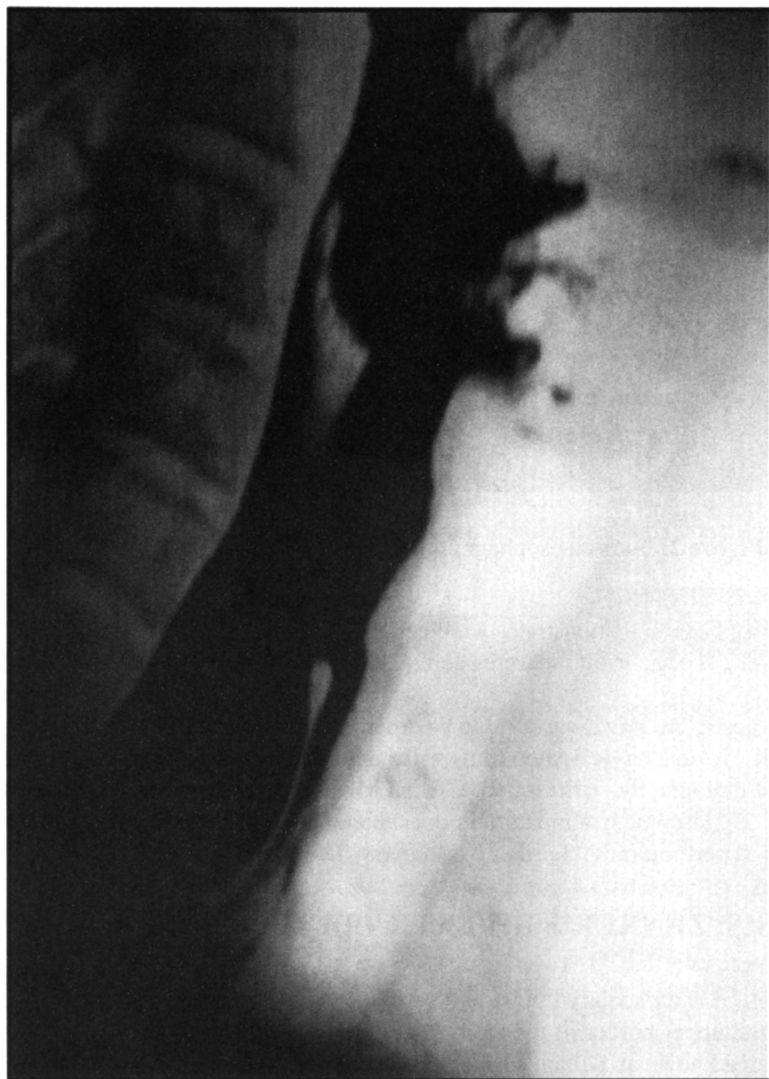

Figure 1. Barium esophagram

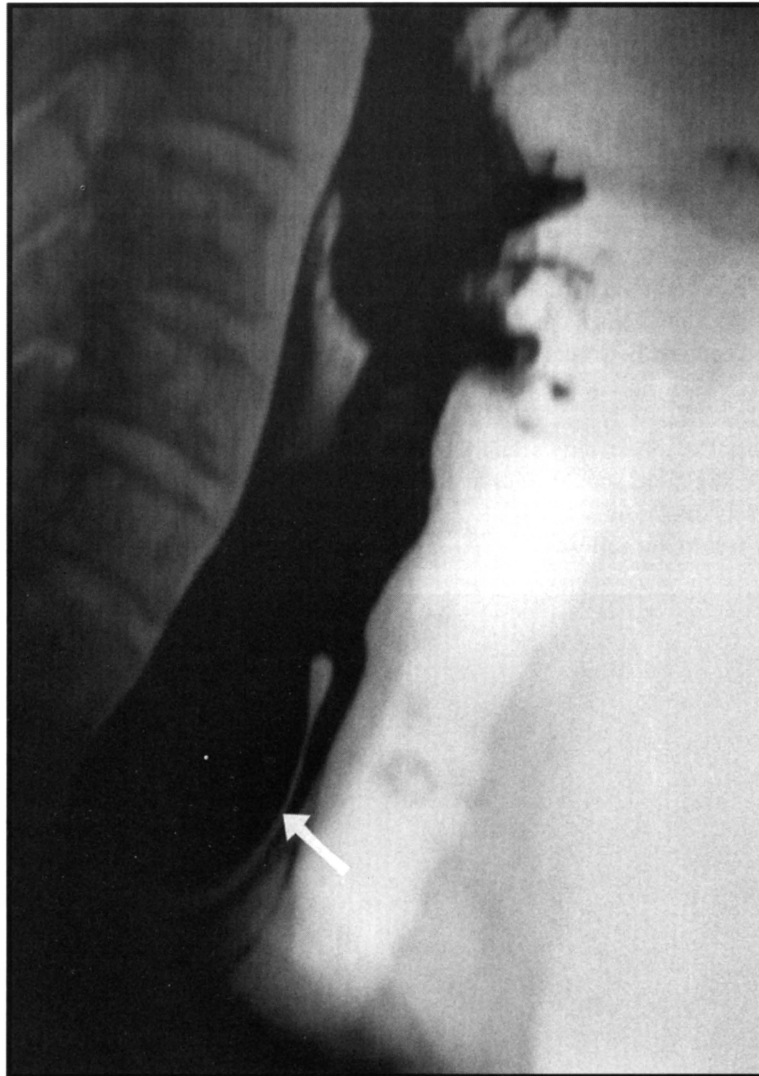


Figure 2. Barium esophagram demonstrating Zenker's diverticulum

A1: The barium esophagram demonstrates a collection of radiopaque barium outlining a left-sided esophageal diverticulum at the C5-C6 level. The sac itself measures 6cm x 3cm, and appears regular with no filling defects.

A2: No other diagnostic investigations need to be ordered as the barium swallow is the “gold standard” for evaluating this lesion¹. Occasionally, lateral cervical plain films will suggest the presence of a diverticulum, but this result will only lead to ordering the contrast radiography. Ultrasound, CT and MRI do not appear to give more information unless a malignancy is being considered. Endoscopic examination is not recommended as it is not felt to offer further information and carries increased risks such as perforation¹⁻³. Further workup may later be necessary if the patient is to undergo surgery.

A3: DIAGNOSIS: ZENKER'S DIVERTICULUM

A Zenker's diverticulum is an acquired pulsion diverticulum of the upper esophagus. It occurs through an area of natural weakness between the upper border of the cricopharyngeal muscle and the lower border of the inferior constrictor muscle of the pharynx, an area known as Killian's triangle. Clinically this corresponds to the C5-C6 level³⁻⁵. These diverticula were first described by Ludlow in 1769 and later examined by Zenker and von Ziemssen in 1877^{4,6,7}. Based on their anatomical location, these lesions are also known as hypopharyngeal or pharyngoesophageal diverticula.

Zenker's diverticula are more common in males (3:1), often in the 6th or 7th decades of life. It is primarily a disease of the middle to older age group. Patients often display other GI pathology such as hiatal hernia or gastroesophageal reflux, however the relationship between these conditions remains unclear^{1,3,4,6}.

Several theories exist to explain the etiology of a Zenker's diverticulum. Most are based on pathology in the upper esophageal sphincter (UES), leading to increased intrabolus forces and the eventual formation of a pulsion diverticulum. Cricopharyngeal spasm, incomplete relaxation of the UES, sphincter-esophageal incoordination, and other pathological, enzymatic and functional changes in the cricopharyngeus have all been described as etiologies of pharyngoesophageal diverticula²⁻⁸.

The diagnosis is based on an accurate history and physical examination and is confirmed by a barium esophagram. Dysphagia is the most common complaint, although frequent regurgitation of undigested food, halitosis, globus sensation and aspiration are also commonly seen. Voice changes, cough, weight loss, choking, odynophagia and neck pain have also been described¹⁻⁸. Physical examination is often completely normal, although in some patients a soft, compressible mass may be palpable on the lateral aspect of the neck, usually on the left^{2,3}. On barium study, if the sac appears irregular or has fixed filling defects malignancy must be ruled out. Although rare (0.4%), the presence of cancer in the diverticulum has been reported^{2,8}. Hypopharyngeal diverticula are found incidentally in about 2% of upper GI radiographic studies and may be noted as air-filled sacs or cystic shadows on routine chest films².

A4: TREATMENT OPTIONS

There is little in the way of medical management available for these patients and there is currently no drug available to alter the underlying pathology responsible for diverticulum formation⁸. For asymptomatic patients, treatment is observational and the patient is instructed to chew food carefully, increase fluid intake at mealtime, avoid lying down after meals and avoid nocturnal snacks^{2,3}. Once the diagnosis of a Zenker's diverticulum is made, however, the sac can be expected to progress, and most head and neck surgeons will advocate some sort of surgical intervention for symptomatic patients^{4,6,7,8}. There are two main categories of surgical therapy available: open surgical (external) approach and endoscopic approach.

Open surgical procedures include cricopharyngeal myotomy (CPM), diverticulopexy (suspension of the sac), diverticulectomy (excision of the sac), and imbrication (inversion) of the sac into the esophageal lumen. The cricopharyngeus muscle is paramount in this disease and most agree that a CPM, done alone or in combination with another procedure, is a necessary aspect of treatment⁴. Sus-

pension of the sac offers the advantages of not opening the esophageal lumen, allowing oral intake on the first post-operative day and having a decreased risk of postsurgical complications. With this procedure, however, no surgical specimen is sent to the lab, allowing potential for missing an occult cancer^{3,8}. Pouch inversion offers similar characteristics as diverticulopexy, but limited long-term information is available. Diverticulectomy has the advantage of surgical specimen evaluation but generally leads to longer OR and hospitalization times, longer time to oral feeding, increased complications and increased overall cost^{3,8}. Surgical complications to be aware of include mediastinitis, recurrent laryngeal nerve injury and esophagocutaneous fistula^{1,5,6}.

The endoscopic approach is considered by many to be a simple and cost-effective method of treating this disease. Examples include endoscopic diverticulotomy using either diathermy cautery (Dohlman procedure), CO₂ laser, KTP/532 laser, or endoscopic stapling. Simple sphincter dilation may also be done. Endoscopic procedures generally lead to shorter anaesthetic and hospitalization times but require expensive equipment and user expertise. Furthermore, the recurrence rate of the diverticulum tends to be higher when treated endoscopically. This occasionally leads to an open surgical procedure done years later^{2,3,8,9}. Although there is a general decrease in post-operative morbidity, the incidence of perforation, hemorrhage and stricture are increased using this technique^{6,8,9}.

The optimal surgical treatment of these diverticula remains controversial and excellent results have been reported using each of the various surgical techniques¹⁻⁹. Due to its short anaesthetic time and decreased morbidity, the endoscopic approach is best for elderly patients or those at increased operative risk. Myotomy alone seems to be sufficient for smaller diverticula, while diverticulopexy and diverticulectomy are more appropriate for larger sacs. Sac excision should always be done if malignancy is suspected.

REFERENCES

1. Levine PA. Hypopharyngeal Diverticulum. In: Gates, ed. *Current Therapy in Otolaryngology – Head and Neck Surgery*, 5th ed. St. Louis: Mosby Year Book Inc., 1994:498-500
2. Rakel RE, ed. *Conn's Current Therapy 1999*. Philadelphia: W.B. Saunders Co., 1999:480-481
3. Nemechek AJ, Amedee RG. Zenker's Diverticula. *J La State Med Soc* 1996; 148(2):49-53
4. Bonafede JP, Lavertu P, Wood BG, Eliachar I. Surgical Outcome in 87 Patients with Zenker's Diverticulum. *Laryngoscope* 1997; 107: 720-725

DIAGNOSTIC CHALLENGE: ANSWERS

5. Laccourreye O, Menard M, Cauchois R, Huart J, Jouffre V, Brasnu D, Laccourreye H. Esophageal Diverticulum: Diverticulopexy versus Diverticulectomy. *Laryngoscope* 1994; 104:889-92
6. VonDoersten PG, Byl FM. Endoscopic Zenker's Diverticulotomy (Dohlman Procedure): Forty Cases Reviewed. *Otolaryngol Head Neck Surg* 1997; 116:209-212
7. Witterick IJ, Gullane PJ, Yeung E. Outcome Analysis of Zenker's Diverticulectomy and Cricopharyngeal Myotomy. *Head & Neck* 1995; 17:382-388
8. Sideris L, Chen LQ, Ferraro P, Duranceau AC. The Treatment of Zenker's Diverticulum: A Review. *Seminars in Thoracic and Cardiac Surgery* 1999; 11(4): 337-351
9. Bradwell RA, Bieger AK, Strachan DR, Homer JJ. Endoscopic Laser Myotomy in the Treatment of Pharyngeal Diverticula. *Journal of Laryngology and Otology* 1997; 111:627-630